


**PATIENT PRESENTING CLINICAL SIGNS**

Hunter Harrison History: chx of new onset seizures in the last 24 hours, Hx of liver "spots"

**SPECIES**

Abnormal PE/Chem/CBC/UA Results: BUN 36.6, Lipase >1000, Chol >450, ALP >993, CA 12.4, ALT 560, AST 66, GGT 30

Canine

**ULTRASONOGRAPHIC EXAMINATION OF THE ABDOMEN**
**BREED**
**Urinary System**

Jack Russel Terrier

The urinary bladder wall is normal in thickness and the mucosal surface is smooth. The bladder is moderately distended. Luminal contents are anechoic. No cystic calculi are observed. The region of the trigone and the proximal urethra, visible to a depth of 2 cm, are normal.

**SEX**

The prostate is normal in size (0.84 cm in width) and shape. Parenchyma is homogenous. The prostatic urethra appears normal without evidence of dilation or obstruction.

Neutered Male

**AGE**

The left kidney is normal in size (5.67 cm in length) with an irregular shape. The cortex is isoechoic relative to the spleen. There is mild to moderate loss of corticomedullary distinction. Several hyperechoic shadowing diverticular foci are observed. Mild to moderate pyelectasia is present (0.40 cm in the longitudinal plane). A cortical infarct is suspected at the caudolateral aspect. There is no evidence of hydronephrosis.

15 years

**WEIGHT**

The right kidney is normal in size (6.49 cm in length) with a normal shape, smooth peripheral margins, and normal internal architecture. The cortex is isoechoic relative to the spleen. There is mild loss of corticomedullary distinction. Several hyperechoic shadowing diverticular foci are observed. There is no evidence of pyelectasia, infarcts or hydronephrosis.

10.9 kg

**INTERPRETED BY**
**Adrenal Glands**

Andrea Nicastro, DVM,  
 Diplomate ACVIM  
 (Small Animal Internal  
 Medicine)

What is thought to be the caudal pole is normal in size (0.52 cm in width) with a normal shape and glandular echogenicity and detail. Surrounding vasculature appears normal.

One still image is available for interpretation. The right adrenal gland is enlarged (1.56 cm at cranial pole) (1.40 cm at caudal pole) (2.82 cm in length) with a slightly irregular shape. The parenchyma appears mildly heterogenous with loss of glandular detail.

**IMAGING PERFORMED BY**
**Spleen**

Hayley Heindel, CVT

The spleen is normal in size (1.33 cm in width at the level of the hilus) with normal curvilinear peripheral contours. The parenchyma is subtly mottled in appearance with a coarse echotexture. Pinpoint hyperechoic foci are observed throughout the organ. Splenic vasculature is normal with no obvious evidence of evidence of thrombosis.

**HOSPITAL NAME**

Mason Dixon Animal  
 ER

**Liver**
**REFERRING VET**

Dr. Spiga

The liver is subjectively enlarged with swollen, slightly irregular peripheral contours. The parenchyma is isoechoic relative to the spleen and subtly heterogenous in appearance, with a coarse echotexture. An approximately 3.80 cm isoechoic-to-slightly-hyperechoic swelling /mass is observed deep on the left side. A few small, ill-defined hyperechoic nodules are also seen. Hepatic vasculature and intrahepatic biliary tracts are of normal volume with no evidence of congestion.

**INVOICE**

The gall bladder is moderately distended. The wall is normal in thickness. Several polypoid-like lesions are arising from the luminal surface. A moderate amount of echogenic debris/sludge is observed within the lumen (some of which is partially dependent and some of which is suspended). The cystic and common bile ducts are normal/not seen.

12662

**DATE**

4.4.23

### ***Gastrointestinal***

The stomach and intestine are free of stasis and exhibit normal peristaltic activity. The gastric lumen is not distended. The gastric wall and pylorus are normal in thickness with a normal layering pattern. The pyloric outflow tract is patent. The small intestinal lumen is not dilated. The small intestinal wall is normal in thickness with a normal layering pattern and appropriate mural detail. Discreet masses are not identified. The colonic wall is normal. There is no evidence of an obstructive pattern.

### ***Pancreas***

The left limb and base of the pancreas are visible with normal curvilinear peripheral contours. The parenchyma is largely isoechoic relative to surrounding omental fat and slightly mottled in appearance. The pancreatic duct is visible but not overtly dilated. There is no evidence of peripancreatic inflammation or effusion.

### ***Free Abdomen***

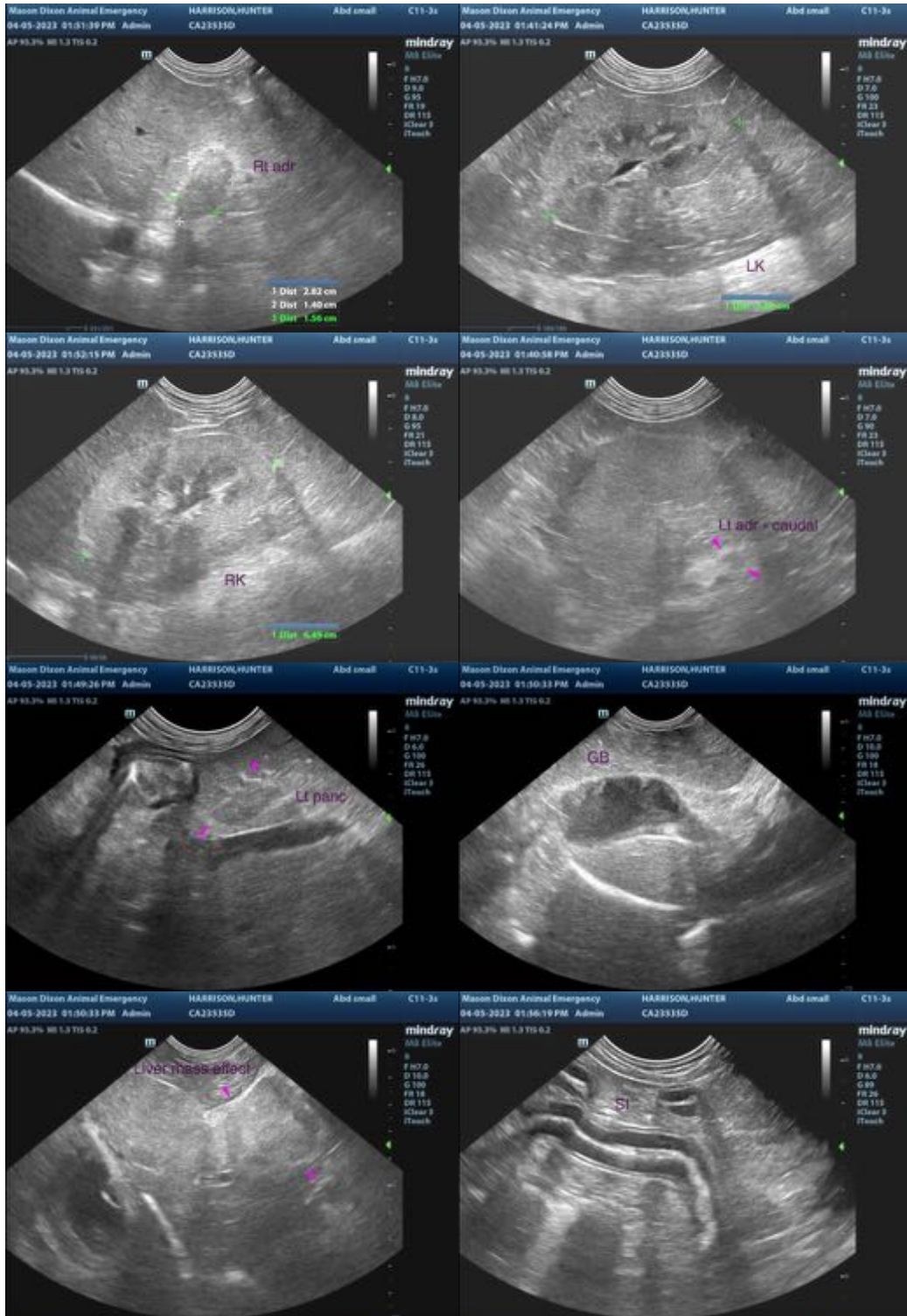
The peritoneal cavity is normal. There is no evidence of inflammation or effusion. The abdominal lymph nodes are normal/not visible.

## **INTERPRETATION OF THE FINDINGS & FURTHER RECOMMENDATIONS**

- The hepatic swelling/mass could be consistent with an emerging tumor (i.e., adenoma, adenocarcinoma, round cell tumor) or a benign process (i.e., focal inflammatory lesion, regenerative nodule). The diffuse hepatic parenchymal changes are nonspecific and could be consistent secondary to regenerative nodular hyperplasia, vacuolar hepatopathy, inflammatory disease, hepatotoxicosis (i.e., copper, infiltrative neoplasia, other hepatopathy or some combination thereof).

### **Secondary Findings**

- Bilateral chronic age-related renal changes with dystrophic mineralization and left pyelectasia with cortical infarct.
- The right adrenomegaly is most consistent with hyperplastic change with a lower possibility of an emerging tumor.
- The gall bladder changes could be secondary to fasting, cholestasis or an emerging mucocele.
- The pancreatic changes are most consistent with age-related parenchymal remodeling, potentially secondary to a prior inflammatory episode, early fibrosis or chronic pancreatitis.
- The splenic parenchymal changes are most consistent with a benign process such as lymphoid hyperplasia, extramedullary hematopoiesis, splenitis or antigenic stimulation with a low possibility of infiltrative neoplasia (i.e., lymphoma, mast cell neoplasia). There is evidence of dystrophic mineralization of the spleen. This is also a benign incidental finding associated with endocrinopathies.



The information and recommendations provided are based on the images presented by the referring veterinarian/sonographer. No evaluation can be communicated regarding pathology that was not visible in

**the image/video clips provided.**

Thank you for this referral. If the clinical or image interpretation does not parallel your findings or if I can be of any further assistance, please contact me.

**Andrea Nicastro**, MPH, DVM, Diplomate DACVIM (Small Animal Internal Medicine)  
[info@SonoPath.com](mailto:info@SonoPath.com)